

Effectiveness of EDTA 17% in the removal of smear layer and calcium hydroxide dressing from the root canal walls

Efetividade do EDTA 17% na remoção da smear layer e da medicação intracanal de hidróxido de cálcio das paredes dos canais radiculares

Rosana de Souza PEREIRA¹

Patrícia Fernando MIRANDA²

Gisela de Souza PEREIRA¹

Juliana Machado BARROSO³

Márcia Gabriella Lino de Barros BORTOLOTTI⁴

José Luiz Cintra JUNQUEIRA⁴

ABSTRACT

Objective

To evaluate the effectiveness of EDTA 17% on the removal of the smear layer and the calcium hydroxide dressing in different thirds of the root canal.

Methods

Forty canines were instrumented in the cervical and middle thirds using Gates-Glidden drills. In the working length, enlargements were carried out with files up to #35 followed by scaling up to #50. After instrumentation, the teeth were divided into four groups according to the type of final irrigation: Group I - irrigation with 5 ml NaOCl 2.5%, Group II - irrigation with 5 ml EDTA 17% followed by irrigation with 5 ml NaOCl 2.5%; Group III - irrigation with 5 ml NaOCl 2.5%; Group IV - irrigation with 5ml EDTA 17% followed by one with NaOCl 2.5%. The teeth were filled and radiographed. The teeth were then submitted to the clearing technique and photographed by means of a camera coupled to a stereomicroscope.

Results

The images showed: Group I - the presence of smear layer in the three thirds and fewer accessory canals filled; group II - the smaller amount of smear layer on the cervical, middle and apical third and filling of the accessory canals; group III - there are residues from the dressing in the cervical, middle and apical third, and group IV - in all of the thirds there was a reduction in the presence of dressing remnants and the largest number of filled accessory canals

Conclusion

It can be concluded that the use of EDTA 17% favored the removal of the smear layer and the remnants of the intracanal dressing in all thirds of the root canal.

Indexing terms: Calcium hydroxide. Dental pulp cavity. Edetic acid. Smear Layer.

RESUMO

Objetivo

Avaliar a eficácia do EDTA a 17% na remoção da smear layer e da medicação de hidróxido de cálcio nos diferentes terços do canal radicular.

Métodos

Quarenta caninos inferiores foram instrumentados nos terços cervical e médio utilizando-se brocas Gates-Glidden. No comprimento de trabalho realizou-se o alargamento até a lima #35 seguido do escalonamento até a lima #50. Após os dentes foram divididos em quatro grupos de acordo com a irrigação final: grupo I - irrigação com 5ml de NaOCl 2,5%; grupo II - irrigação com 5 ml de EDTA 17% seguidos de 5ml de NaOCl 2,5%; grupo III - irrigação com 5ml de NaOCl 2,5%; grupo IV - irrigação com 5ml de EDTA 17% seguidos de NaOCl 2,5%. Os dentes foram obturados e radiografados. Posteriormente os dentes foram diafanizados e fotografados por meio de máquina fotográfica acoplada em lupa estereoscópica.

Resultados

As imagens revelaram: grupo I - presença de smear layer nos três terços e o menor número de canais acessórios preenchidos; grupo II - nota-se a menor quantidade de smear layer no terço cervical, médio e apical e a obturação de canais acessórios; grupo III - há presença de resíduos da medicação no terço cervical, médio e apical; grupo IV - em todos os terços houve redução da presença de resíduos da medicação e o maior número de canais acessórios preenchidos.

Conclusão

Pode-se concluir que o uso do EDTA a 17% favoreceu a remoção dos resíduos da medicação intracanal do canal radicular.

Termos de indexação: Hidróxido de cálcio. Cavidade pulpar. Ácido edético. Camada de esfregaço.

¹ Universidade Federal do Espírito Santo, Faculdade de Odontologia Av. Marechal Campos, 1468, Campus Maruípe, 29040-090, Vitória, ES, Brasil. Correspondência para / Correspondence to: RS PEREIRA. E-mail: <rosanadesouzapereira@yahoo.com.br>.

² Associação Brasileira de Odontologia, Seção Vitória, Vitória, ES, Brasil.

³ Escola Superior São Francisco de Assis. Santa Tereza, ES, Brasil.

⁴ Faculdade São Leopoldo Mandic, Curso de Odontologia, Programa de Pós-Graduação em Radiologia. Campinas, SP, Brasil.

INTRODUCTION

The main aim of endodontic treatment is to promote the disinfection, shaping and hermetic sealing of the root canal system. This process is generally achieved using mechanical instrumentation, supplemented by the use of irrigants and antimicrobial agents. Calcium hydroxide (Ca(OH)₂) is the substance most frequently recommended and accepted as intracanal dressing, by virtue of its marked antimicrobial action on the majority of species of bacteria found in endodontic infections¹.

However, remnants of this substance remaining inside the main canal and also the accessory canals enclosed in the smear layer could lead to infiltration at the interface of the canal wall and the filling, so a final irrigation is recommended prior to endodontic filling in order to induce its removal².

The endodontic smear layer has been described as a residual layer that covers the canal walls, produced by the cutting of the dentin surface by the instrument³⁻⁴. The first researchers to describe the smear layer on the instrumented root canal surface were McComb & Smith⁵, who identified the presence, in the composition of the smear layer, not only of dentin shavings but also the remains of odontoblastic processes, namely pulp and bacteria. Violich & Chandler⁴ emphasized that the smear layer is composed mainly of inorganic material, which prevents effective removal using sodium hypochlorite. Some authors suggest the use of sodium hypochlorite combined with a final irrigation using EDTA 17% for the complete removal of the smear layer^{4,6-9}.

In the past, several authors have suggested that the retention of the smear layer could block the dentinal tubules and restrict penetration by bacteria¹⁰⁻¹². However it is now known that this layer, with its weak adherence to the root canal walls, could harbor numerous bacteria and provide a substrate for them¹²⁻¹⁵. Moreover, when present on the wall and the dentinal tubules, it could limit the effectiveness of the disinfection of the root canal system, preventing the action of the sodium hypochlorite during the irrigation with the calcium hydroxide used as intracanal dressing and the endodontic cement during the filling^{4,16}.

Faced with the possibility that using calcium hydroxide leaves debris inside the canal, together with the residual dentin layer, possibly exerting a negative effect in terms of the quality of the sealing of the canal filling, concern has grown over the removal technique. Some authors have reported more adequate sealing of the filling when the calcium hydroxide was used as dressing between sessions and also as an apical plug¹⁷. Some theories suggest

that calcium hydroxide, when it comes into contact with dentin, is capable of reducing its permeability, while others argue for its inclusion in the filling cement, providing by itself a reduction in permeability¹⁸. Given its ability to chelate calcium ions, EDTA has also been recommended in the removal of calcium hydroxide from the inside¹⁹.

The aim of the present study, therefore, was to evaluate the effectiveness of edetic acid at 17% (EDTA 17%) in the removal of the smear layer and of the calcium hydroxide intracanal dressing on the different thirds of the root canal.

METHODS

A total of 40 extracted single-rooted, human, lower canines were used. Surgery was initially carried out to access and remove the pulp tissue, using a high-speed no. 2 spherical diamond bur (KG-Sorensen, São Paulo, Brazil) cooled with water, followed by copious irrigation of the pulp chamber with a solution of sodium hypochlorite 1% and suction. Each root canal was examined with the aid of a size 10 k-type file (Dentsply, Maillefer, Ballaigues, Switzerland), along the entire length as far as the apical foramen. Retreating one millimeter from this length, the actual working length of each sample was obtained, with the vestibular cusp of this same root being the point of reference used as the parameter for this definition.

The teeth were then instrumented using Gates-Glidden 32 mm bits in the sequence #4, #3, #2, #1 to within 4 mm of the root apex. In the working length, the instrumentation began with the use of file #15 and proceeded up to file #35, finishing at the apical stop and the scaling was performed using files 40, 45 and 50.

After the biomechanical preparation, the teeth were divided at random into four distinct groups according to the type of final irrigation used: group I - the irrigation was carried out using 5 ml of sodium hypochlorite 2.5%. The teeth were dried with absorbent paper points and sealed with zinc oxide and eugenol; group II - the teeth were irrigated with 5 ml EDTA 17% for two and a half minutes, subjected to agitation with a #15 file, followed by irrigation with 5 ml of NaOCl 2.5%. The teeth were dried with absorbent paper points and sealed with zinc oxide and eugenol; group III - after the application of Ca(OH)₂ intracanal dressing combined with propylene glycol, these teeth also received a final irrigation with 5 ml NaOCl 2.5% and agitation with a file. The teeth were

dried with absorbent paper points and sealed with zinc oxide and eugenol; group IV - after the use of the Ca(OH)_2 intracanal dressing combined with propylene glycol for 5 days, irrigation was performed with 5 ml EDTA 17% for two and a half minutes, submitted to agitation using a #15 file, followed by the use of absorbent paper points and sealed with zinc oxide and eugenol.

The teeth were subsequently filled using the McSpadden technique. They were then radiographed in the vestibular-lingual and mesial-distal directions and submitted to the clearing technique. In this process, the teeth were immersed in HCl 10% for 24 hours, with daily replacement, until the rubbery condition of the tooth was evident. The teeth were rinsed in running water for 24 hours. The next dehydration phase was carried out using the gradual addition of alcohol (50% of pure alcohol) for one hour, and for the final pass it remained for 24 hours. After dehydration, the samples were inserted in Methyl Salicylate, where they were kept. After the teeth reached a state of total transparency, photographs were taken with the aid of a camera attached to a stereoscopic magnifying glass.

RESULTS

In group I, the presence of a smear layer was observed, left by the compact instrumentation in the middle of the filling material (Figure 1a) which was not removed by the NaOCl 2.5%, and complementing this observation, a reduction can be seen in the sharpness of the edge of the filling (Figure 1b). Additionally, the smaller number of filled accessory canals can be observed.

When we analyze group II, we find that in the cervical, middle and apical thirds, a smaller quantity of smear layer is present and the filling of accessory canals (Figures 1c and 1d) characterized by the use of NaOCl 2.5% combined with EDTA 17% without the use of intracanal dressing.

Group III shows the presence of dressing residue in the cervical, middle and apical thirds (Figures 1e and 1f).

In group IV, in all the thirds, the largest number of filled accessory canals is evident as well as the presence of sharper edges and a reduced presence of smear layer (Figures 1g and 1h).

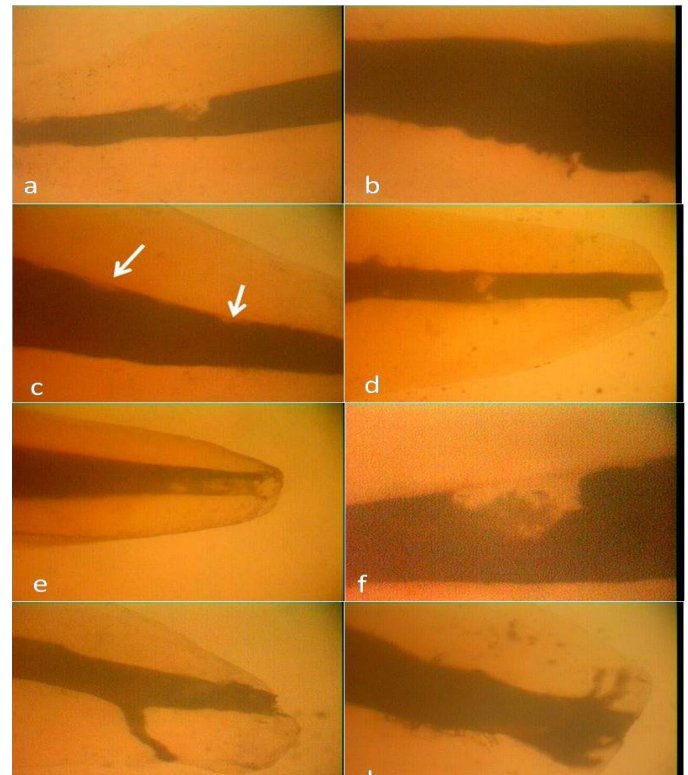


Figure 1. Morphological analysis- A: Group 1 (Control). Root surface with intact cementum (score 1); B: Group 2 (SRP). Smooth and regular root surface, with occluded dentinal tubules, and presence of smear layer (score 2); C: Group 3 (Ultrasonic scaler). Irregular root surface with presence of grooves, occluded dentinal tubules, and smear layer (score 3); D: Group 4 (Ultrasonic scaler+SRP). Irregular root surface with presence of grooves, occluded dentinal tubules, and smear layer (score 3) (bar:10µm; original magnification: X 1000).

DISCUSSION

Despite it being a subject that courts controversy, there is a tendency in the literature for the recommendation of the removal of the smear layer and the potential residue left by the calcium hydroxide, assuming that this is a beneficial procedure to achieve the filling of the entire root canal system^{4,16,18}.

Many solutions are tested with this end in mind, however the solution involving EDTA and its combinations is the one most frequently used by virtue of its satisfactory chelating properties^{4,6-9}.

Analyzing the photographs for group I, it can be observed that only the use of the hypochlorite solution was incapable of removing the smear layer from the canal walls as its presence can be seen in the filling material, which could be explained by the fact that the smear layer is composed of both organic and inorganic products, which requires the use of a solution to complement the action of

the hypochlorite, which only works on the organic portion of this layer. Meanwhile, in group II, where EDTA was employed, the presence of filled accessory canals can be observed. These findings agree to the study by White et al.⁶ and Violich & Chandler⁴.

In group III, the presence of a smear layer and calcium hydroxide residue was more accentuated in all three thirds, not only on the walls but also inside the filling material, which may be explained by the looser adherence of calcium hydroxide to the dentin walls when compared to the smear layer, which is in line with observations made by Miranda²⁰.

The importance of using EDTA, for the removal of both the smear layer and the calcium hydroxide dressing, was demonstrated by Moraes et al.¹⁹. It was reaffirmed by Calt & Seper¹⁸, who highlighted the use of Ca(OH)₂ as an intracanal dressing, that it should be completely removed from the root canal walls using EDTA, followed by NaOCl, to enable the effective sealing of the root canal and the penetration of the cement inside the root canals. In comparative studies, the authors debunked the argument that, even with the use of these solutions, it was not possible to remove the Ca(OH)₂ completely from the canal.

In group IV, where EDTA was used combined with hypochlorite in the removal of the calcium hydroxide

the reduction of smear layer was found on the walls through the presence of sharp edges and also the Ca(OH)₂ dressing via the reduction of spaces in the middle of the filling material, unlike in group III, which indicated a possible effectiveness of EDTA in the removal of Ca(OH)₂ residue, as well as the already established effectiveness on the smear layer²¹.

CONCLUSION

According to the methodology employed and the results obtained, it may be concluded that the use of EDTA 17% benefitted the removal of the smear layer and the intracanal dressing residues in all thirds of the root canal.

Collaborators

RS PEREIRA, PF MIRANDA, GS PEREIRA, JM BARROSO, MGLB BORTOLOTTI and JLC JUNQUEIRA took part in all stages of the preparation of this article.

REFERENCES

1. Bystrom A, Claesson R, Sundqvist G. The antibacterial effect of camphorated paramonochlorophenol, camphorated phenol and calcium hydroxide in the treatment of infected root canals. *Endod Dent Traumatol.* 1985;1(5):170-5. doi: 10.1111/j.1600-9657.1985.tb00652.x.
2. Lui JN, Kuah HG, Chen NN. Effect of EDTA with and without surfactants or ultrasonics on removal of smear layer. *J Endod.* 2007;33(4):472-5. doi: 10.1016/j.joen.2006.12.007.
3. Daghustani M, Alhammadi A, Merdad K, Ohlin J, Erhardt F, Ahlquist M. Comparison between high concentration EDTA (24%) and low concentration EDTA (3%) with surfactant upon removal of smear layer after rotary instrumentation: a SEM study. *Swed Dent J.* 2011;35(1):9-15.
4. Violich DR, Chandler NP. The smear layer in endodontics: a review. *Int Endod J.* 2010;43(1):2-15. doi: 10.1111/j.1365-2591.2009.01627.x.
5. McComb D, Smith DC. A preliminary scanning electron microscopic study of root canals after endodontic procedures. *J Endod.* 1975;1(7):238-42. doi: 10.1016/S0099-2399(75).
6. White RR, Goldman M, Lins PS. The influence of the smeared layer upon dentinal tubule penetration by plastic filling materials. *J Endod.* 1984;10(12):558-62.
7. Baumgartner JC, Mader CL. A scanning electron microscope evaluation of four root canal irrigation regimens. *J Endod.* 1987;13(4):147-57.
8. Câmara AC, Albuquerque MM, Aguiar CM. Soluções irrigadoras utilizadas para o preparo biomecânico de canais radiculares. *Pesq Bras Odontoped Clin Integr.* 2010;10(1):127-33. doi: 10.4034/1519.0501.2010.0101.0021
9. Khedmat S, Shokouhinejad N. Comparison of the efficacy of three chelating agents in smear layer removal. *J Endod.* 2008;34(5):599-602. doi: 10.1016/j.joen.2008.02.023
10. Michelich VJ, Schuster GS, Pashley DH. Bacterial penetration of human dentin in vitro. *J Dent Res.* 1980;59(8):1398-403. doi: 10.1177/00220345800590080701.
11. Pashley DH, Michelich V, Kehl T. Dentin permeability: effects of smear layer removal. *J Prosthet Dent.* 1981;46(5):531-7.
12. Dechichi P, Moura CCG. Smear layer: a brief review of general concepts. Part I. Characteristics, compounds, structure, bacteria and sealing. *RFO UPF.* 2006;11(2):96-9.
13. Mader CL, Baumgartner JC, Peters DD. Scanning electron microscopic investigation of the smeared layer on root canal walls. *J Endod.* 1984;10(10):477-83. doi: 10.1016/S0099-2399(84)80204-6.

14. Cameron JA. The synergistic relationship between ultrasound and sodium hypochlorite: a scanning electron microscope evaluation. *J Endod.* 1987;13(11):541-5. doi: 10.1016/S0099-2399(87)80034-1.
15. Meryon SD, Brook AM. Penetration of dentine by three oral bacteria in vitro and their associated cytotoxicity. *Int Endod J.* 1990;23(4):196-202. doi: 10.1111/j.1365-2591.1990.tb00100.x.
16. Torabinejad M, Handysides R, Khademi AA, Bakland LK. Clinical implications of the smear layer in endodontics: a review. *Oral Surg Oral Med Oral Pathol Oral Radiol Endod.* 2002;94(6):658-66. doi: 10.1067/moe.2002.128962.
17. Holland R, Alexandre AC, Murata SS, dos Santos CA, Dezan Júnior E. Apical leakage Following root canal dressing with calcium hydroxide. *Dental Traumatol.* 1995;11(6):261-9. doi: 10.1111/j.1600-9657.1995.tb00500.x.
18. Calt S, Serper A. Dentinal tubule penetration of root canal sealers after root canal dressing with calcium hydroxide. *J Endod.* 1999;25(6):431-3. doi: 10.1016/S0099-2399(99)80273-8.
19. Moraes IG, Nunes E, Berbert A, Duarte MAH, Betti LC. Influência do calcium hydroxide e do EDTA na marcação da infiltração marginal de azul de metileno em obturação de canais radiculares. *Rev Fac Odontol Bauru.* 2000;8(12):37-44.
20. Miranda PF. Influência da medicação curativa intracanal (Ca(OH)₂) sobre a obturação do sistema de canais radiculares [Monografia]. Vitória: Associação Brasileira de Odontologia; 2004.
21. Moraes IG, Nunes E, Berbert A, Duarte MAH, Betti LC. Influência do calcium hydroxide e do EDTA na marcação da infiltração marginal de azul de metileno em obturação de canais radiculares. *Rev Fac Odontol Bauru.* 2000;8(12):37-44.
22. Paqué F, Boessler C, Zehnder M. Accumulated hard tissue debris levels in mesial roots of mandibular molars after sequential irrigation steps. *Int Endod J.* 2011;44(2):148-53. doi: 10.1111/j.1365-2591.2010.01823.x.

Received on: 17/8/2011

Final version resubmitted on: 24/11/2011

Approved on: 7/1/2012