

Transmigrated teeth

Transmigração dentária

João Renato CORSI¹

Paulo de Camargo MORAES¹

Daniela Prata TACHELLI¹

Cláudio Roberto Pacheco JODAS¹

José Luiz Cintra JUNQUEIRA¹

Rubens Gonçalves TEIXEIRA¹

ABSTRACT

Pre-eruptive migration of a tooth across the midline is called transmigration. This article reviews the literature on tooth transmigration. In the literature there is no consensus on the definition of true cases of transmigration and impacted teeth. Transmigration is a rare phenomenon that typically affects the mandibular canines. There is no known etiology for its occurrence, however, there are many and varied etiological factors involved in transmigrated teeth, such as ectopic growth of the tooth bud, retention or premature loss of a primary tooth, inadequate eruption space and excessive length of crown. Genetic factors, endocrine disorders and trauma have also been also proposed as etiological factors. In most clinical reports, transmigrated teeth were found in a horizontal position, below the apices of the erupted teeth and in the majority of cases, such a migrated tooth remains impacted; however, it may sometimes erupt later in its new position. When it is diagnosed in radiographic exams, careful evaluation is necessary in order to establish the most adequate treatment. Extraction of the transmigrated tooth appeared to be the only choice of treatment.

Indexing terms: Diagnosis. Impacted Tooth. Tooth Migration.

RESUMO

A migração pré-eruptiva de um dente através da linha média é chamada de transmigração. O objetivo deste artigo é apresentar uma revisão da literatura sobre a transmigração dentária. Na literatura não há consenso sobre a definição de casos de verdadeiros de transmigração e dentes impactados. Transmigração é um fenômeno raro, que normalmente afeta os caninos inferiores e a sua etiologia é desconhecida, porém vários fatores etiológicos podem estar envolvidos nos casos de transmigração, tais como o crescimento ectópico da raiz do dente, retenção ou perda prematura de um dente decíduo, espaço insuficiente erupção e comprimento excessivo da coroa. Fatores genéticos, doenças endócrinas e trauma também foram citados como possíveis fatores etiológicos. Nos relatos clínicos os dentes transmigrados foram encontrados em posição horizontal, abaixo os ápices dos dentes irrompidos e na maioria das vezes, um dente com transmigração permanece impactado; no entanto, posteriormente, pode irromper em sua nova posição. Quando diagnosticado, por exames radiográficos, é necessário um planejamento criterioso para o estabelecimento do tratamento mais adequado. A exodontia é o tratamento de escolha para os casos de transmigração dentária.

Termos de indexação: Diagnóstico. Dente Impactado. Migração de Dente.

INTRODUCTION

Pre-eruptive migration of a tooth across the midline is called transmigration¹. Transmigration is a rare phenomenon, which typically affects the mandibular canines, but rarely also occurs in maxillary canines².

There is not a great deal of literature specifically about the incidence of transmigration. A recent study in a Turkish subpopulation, found an incidence of 0.34% of transmigrated maxillary and mandibular canine teeth (17

patients, 12 females and 5 males, with a mean age of 34 years and 0.14 per cent (7 patients, 4 females/3males, with a mean age of 37.1 years³, respectively.

The etiology of transmigration is unknown; however, abnormal displacement of the tooth bud or deviation during development is the most commonly accepted explanation⁴. Studies have suggest that proclination of the lower incisors, increased axial inclination of the unerupted canine and an enlarged symphyseal cross-sectional of the chin could play an important role in the mechanism of transmigration. They further stated that

¹ Faculdade São Leopoldo Mandic, Curso de Odontologia. Rua Dr. José Rocha Junqueira, 13, Swift, 13045-755, Campinas, SP, Brasil. Correspondência para / Correspondence to: RG TEIXEIRA. E-mail: <rgte@terra.com.br>.

it is possible for the unerupted canine to deviate from its normal development site, move to a horizontal position, and migrate through the symphyseal bone, only if there is enough space available in front of the mandibular incisor roots. In the majority of cases, such a migrated tooth remains impacted; however, it may sometimes erupt later in its new position⁵.

In most reports of transmigrated teeth they were found in a horizontal position, below the apices of the erupted teeth⁶. Clinical and radiographic examination is usually required to diagnose transmigrant, because they are usually found within the symphysis of the mandible. Transmigrating teeth usually remain impacted and asymptomatic or they can cause pressure resorption of roots or tilting of adjacent teeth.

Decision on surgical removal depends on the symptoms reported by the patient, the site where the tooth is found, and presence of, or no association with pathologies⁷. Figure 1 is a panoramic slice of a cone beam computed tomography scan which revealed an impacted mandibular left premolar. The position of the transversely impacted premolar was unfavorable, so that no orthodontic treatment of this tooth was envisaged and extraction was planned. Figure 2 illustrates a transmigrating mandibular canine. The right canine has crossed the midline.

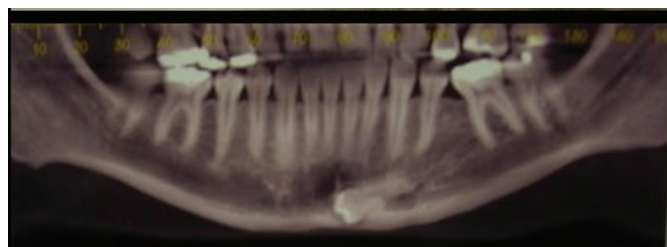


Figure 1. Panoramic slice of a cone beam computed tomography scan that reveal an impacted mandibular left premolar.

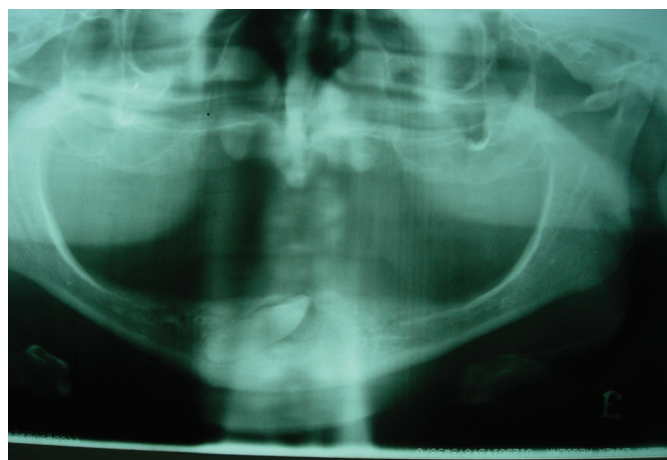


Figure 2. Panoramic radiographic illustrating a transmigrating mandibular canine. The right canine is crossing the midline.

DISCUSSION

Pre-eruptive migration of a tooth across the midline is called transmigration^{4-5,8}. Transmigration of teeth has been identified by a variety of names and there are controversies in the literature regarding the precise definition of transmigration. Recently, Vuchkova and Farah⁹ reported that a large portion of publications cannot be regarded as true cases of transmigration; this being the case when a canine has crossed the midline by more than half its length. However, Javid¹⁰ mentioned that it is not the distance of migration after crossing the midline, but the tendency of a canine to cross the barrier of the mandibular midline suture that is a more important consideration. In addition, Mupparappu¹¹ defined five criteria to classify the transmigrated canine according to its patterns of intra-osseous transmigration.

It is essential to differentiate true cases of tooth transmigration from impacted teeth, and there is no consensus about a definition. Comparisons between case reports should be interpreted with caution due to the lack of uniformity in diagnostic criteria and classification adopted.

There are no well established data for the incidence of transmigrated teeth because reports of transmigrated teeth consist of isolated cases⁸ or small series^{6,9}. The incidence of canine transmigration was greater than its occurrence in other teeth³. To our knowledge, there is only a case report of transmigration of mandibular second premolar in a patient with cleft lip and palate. The authors affirmed that distal migration of the mandibular left second molar premolar is not associated with presence of cleft lip and palate. With the increased use of panoramic radiographs and tomography, it is inevitable that diagnosis of this anomaly will increase.

There are many and varied etiological factors involved in the transmigration of teeth such as ectopic growth of the tooth bud, retention or premature loss of a primary tooth, inadequate eruption space and excessive length of crown. Genetic factors, endocrine disorders and trauma have also been proposed as etiological factors.

CONCLUSION

In conclusion, according to literature there is no consensus on the definition of true cases of transmigration and impacted teeth. Treatment considerations for transmigratory teeth depend on the stage of development and distance of migration at the time they are identified.

When detected early, the tooth can be surgically exposed and moved using orthodontic forces. In addition, when the root apices are closed, extraction often is the only choice. However, the difficulty in removing the tooth in one piece complicates the procedure. Extraction of the transmigrated tooth appeared to be the only choice of treatment. The early detection of this anomaly in patients with missing permanent teeth is essential to the treatment planning.

Collaborators

JR CORSI, PC MORAES, CRP JODAS, DP TACCHELLI helped with the literature search and writing of the manuscript. JLC JUNQUEIRA and RG TEIXEIRA reviewed the manuscript and helped with the final text.

REFERENCES

1. Sumer P, Sumer M, Ozden B, Otan F. Transmigration of mandibular canines: a report of six cases and a review of the literature. *J Contemp Dent Pract.* 2007;8(3):104-10.
2. Aydin U, Yilmaz HH. Transmigration of impacted canines. *Dentomaxillofac Radiol.* 2003;32(3):198-200.
3. Aktan AM, Kara S, Akgünlü F, Malkoç S. The incidence of canine transmigration and tooth impaction in a Turkish subpopulation. *Eur J Orthod.* 2010;32(5):575-81. doi: 10.1093/ejo/cjp151.
4. Alaejos-Algarra C, Berini-Aytes L, Gay-Escoda C. Transmigration of mandibular canines: report of six cases and review of the literature. *Quintessence Int.* 1998;29(6):395-8.
5. Joshi MR, Shetye SB. Transmigrant mandibular canines: a review of the literature and report of two cases. *Quintessence Int.* 1994;25:291-4.
6. Al-Wahedi EMH. Transmigration of unerupted mandibular canines: a literature review and a report of five cases. *Quintessence Int.* 1996;27:27-31.
7. Rebellato J, Schabel B. Treatment of a patient with an impacted transmigrant mandibular canine and palatally impacted maxillary canine. *Angle Orthod.* 2003;73(3):328-36.
8. Camilleri S. Double transmigration and hyperdontia. *Angle Orthod.* 2007;77(4):742-4.
9. Vuchkova J, Farah CS. Canine transmigration: comprehensive literature review and report of 4 new Australian cases. *Oral Surg Oral Med Oral Pathol Oral Radiol Endod.* 2010;109(4):e46-53. doi: 10.1016/j.tripleo.2009.12.031.
10. Javid BR. Transmigration of impacted mandibular cuspids. *Int J Oral Surg.* 1985;14(6):547-9. doi : 10.1016/S0300-9785(85)80063-6.
11. Mupparappu M. Patterns of intra-osseous transmigration and ectopic eruption of mandibular canines: review of literature and report of nine additional cases. *Dentomaxillofac Radiol.* 2002;31(6):355-60.

Received on: 24/5/2010

Final version resubmitted on: 26/9/11

Approved on: 27/11/2011